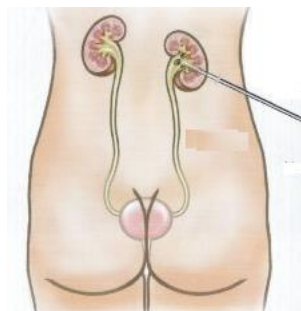


APPENDIX 5

NEPHROSTOMY

(A) NEPHROSTOMY

If obstruction to the ureter(s) develops post-operatively (and was not present pre-operatively), nephrostomy can be a useful procedure to know. Ideally, a nephrostomy set is used e.g. Amecath size 8 or 10 F. If not available, a central venous line can be used instead. Smaller-bore catheters (7-8F) are sufficient for drainage of non-infected urine, while a larger-bore (14F) catheter may be considered for drainage of infected urine or pus.



Position: The patient is placed in the prone position. The posterior approach avoids the surrounding organs.

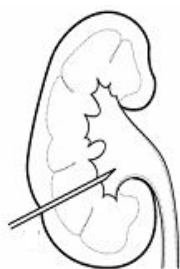Site: about 2 cm below the 12th rib and two finger breadths lateral to the lateral margin of the paraspinous muscles which is approximately the posterior axillary line. Using ultrasound, you can pick the exact site you want to go in i.e. towards a posterior lower-pole calyx.

Anaesthesia: Infiltrate with local anaesthesia at the puncture site.

(1) **Incision:** With a scalpel (no. 11 blade), make a small stab incision through the skin. An artery forceps is then used to dilate the opening in the skin, fascia and muscle superficially.

(2) **Pass needle:** The needle is angled towards the intended calyx usually 45-90 degrees to the horizontal.

Either:



(a) (Using no ultrasound) Pass the needle (21-22 F) with a syringe attached. Aspirate as you insert and stop once urine is obtained.

(b) (Under ultrasound guidance) The needle is inserted below and parallel to the ultrasound probe. Often you can see the movement of the tissues produced by the needle rather than the needle itself. You should see the needle enter the calyces. Once the needle is inserted into the collecting system, the stylet is removed, and urine comes back. If no urine comes, a 10-ml syringe should be attached to the needle hub, and the needle and syringe should be retracted slightly. If urine is aspirated, the tip is probably within the collecting system.

(3) **Insert the guide-wire** through the needle until it is well inside the renal pelvis or down the ureter.

(4) **Remove the needle:** While holding the guide-wire, pull the needle out by grasping the needle at the skin so the depth of the collecting system can then be gauged i.e. measure the depth of the needle e.g. 7 cm. In the remaining steps, this 7 cm depth will be used as the depth recorded.

(5) **Dilators:** Over this guide wire, pass a series of dilators to a depth of where the needle entered i.e. 7 cm. The track is best dilated with a motion that is 80% twist and 20% push.

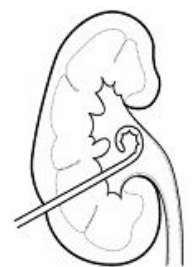(6) **Prepare the catheter:** Prior to introduction, the nephrostomy catheter should be uncoiled. If it is a pig-tail variety this is done by inserting a stylet in the catheter.

(7) **The nephrostomy catheter** is introduced over the guide wire. The catheter with the stylet is introduced to a depth of 7 cm. The stylet is then withdrawn 1-2 cm while the catheter is pushed in 1-2 cm. The catheter can be safely pushed in without injuring the ureter as it will coil up.

(8) Check the flow of urine. You may have to pull back the catheter a bit.

(9) Once the catheter is properly positioned, the wire guide should be removed.

(10) The catheter is tied to the skin with suture and attached to a drainage bag. One of the problems with nephrostomy is preventing it falling out. In addition to sutures, tape the tube to the skin over a roll of gauze at the exit site. The tube is bent over the roll which prevents kinking. The sutures will fall out eventually so you may want to re-stitch it under local anaesthesia every 14 days.



Complications

- Heavy bleeding down the nephrostomy means you have traumatized a parenchymal artery or vein. To stop it, cap the nephrostomy for an hour and then uncap. It usually drains blood stained urine which clears. You may need to flush with 20 ml saline.
- Infection. Give a prophylactic dose of gentamycin or coamoxyclav at the time of insertion.
- Damage to bowel. This is very rare and will only declare some days later with pain, sepsis and spreading tenderness, and may need open exploration.

Nephrostomy care

- Never pull on the tube as it will come out and make sure the tube is not kinked
- Get her to drink plenty to maintain a high dilute urine output
- Drainage bag: Do not let it get heavy as this will displace the tube so empty every 2-3 hours
- If drainage stops it may be blocked with debris or have pulled out of the kidney. Flush with 20 ml saline. Try and withdraw fluid but even if it was blocked and is now unblocked, fluid may not withdraw. In this case, wait and see. If it drains, it was blocked. If it does not drain, it is probably displaced. If you have facilities you can go to X-ray department and inject dye down to confirm. If it is out of the kidney then remove the tube. There is a tiny risk of internal urine leakage. If the nephrostomy needs replacement, wait until the next day for the kidney to dilate and become a good target.

How do you know the nephrostomy is no longer needed and the obstruction has resolved?

- Ideally, do a nephrostogram i.e. inject dye down the tube in X-ray and check the dye enters the bladder. Do not remove straight away – clamp the nephrostomy overnight to ensure it really is draining and remove the next day.
- If you do not have X-ray: Either: (a) Inject blue dye down the nephrostomy. If there is no obstruction then the dye will be seen in the Foley catheter bag (b) Do a trial clamping.

Removing the nephrostomy: Simply cut the stitch and pull. Apply a dressing. Usually there is no leakage.

(B) IS THE KIDNEY STILL FUNCTIONING?

This is a question that arises occasionally in fistula surgery.

- Irreparable damage to the kidney occurs after six weeks of obstruction.
- A pre-operative ultrasound, showing cortical tissue present, suggests that there is still some function present.
- During an abdominal operation if you find one of the ureters is very dilated, try to pass a ureteric catheter. If it does not pass, then the ureter is probably completely occluded or very stenosed and will have no/ very little function. Give a dose of frusemide to see whether there is any urine produced.
- The general advice would be to reimplant an obstructed ureter in cases where there is still some function. If there is no function, it is probably safer to leave it alone although some advise reimplantation in cases of doubt.
- If there is recurrent pyelonephritis and a poorly functioning kidney, it is better to remove the kidney.

Case History: During a VVF repair, the left ureter was explored abdominally and only a small amount of pus drained from it. It was decided to ligate it at the lower end. Post-operatively, the patient developed a pyonephrosis and required an emergency nephrectomy.

Lesson: Re-implantation is done mainly for drainage and in case there is still function. It is not advised to tie off the ureter as this can result in severe sepsis. The only other safe option would be to do a nephrectomy.

(C) NEPHRECTOMY

This is sometimes required as an emergency procedure in fistula surgery. Nephrectomy should preferably be reserved for a non-functioning or poorly functioning kidney.

- *Position:* Patient is supine. Place a roll (e.g. size of a full two litre bag) under the flank to push the kidney into the field.
- *Incision:* Make a midline incision from the xiphoid to the umbilicus. The alternative is to make a subcostal incision starting in the midline. On the right side, use a Deaver retractor to keep the liver up out of way. Cut the peritoneum lateral to the colon with scissors or cautery. Pull the colon medially. On the right side identify the duodenum which overlies the hilum and mobilize it medially.
- *Ureter:* Find the ureter at a convenient level and place a tape around it. It is safer not to cut the ureter until you know you are going to be able to remove the kidney. Slide your hand up the ureter while pulling on the tape. This will lead you towards the hilum i.e. by following the ureter with your finger and thumb, you will approach the hilum from below.

- *Kidney*: Dissect out the anterior, posterior and apical kidney. The key is to stay on the renal cortex as you dissect with your hands and use cautery if necessary. By staying on the cortex, this leaves the adrenal gland (golden fat like appearance) behind, so there is less risk of bleeding.
- *Hilum*: Now lift the kidney up, which gives you more control over the hilum. Come down from above (medial upper kidney) as you come up the ureter from below, and the hilum is what is left. Squeeze the hilum between your finger and thumb. This will tend to get rid of fatty tissue so that you are only left with the vessels.
- *Vessels*: Separate the vessels out using a scissor to tease the tissues apart. Ligate the vessels as you come across them i.e. do whichever one is easier first. The artery is behind the vein on both sides.
- *Ligating*: Place two ties on the medial side and one on the lateral side. Then pass the right-angled clamp under the vessel and cut with a knife onto the clamp. It is a good idea to now transfix the medial side with another suture as ties alone may slip off.

Note: On the left side the kidney has a longer vein into which both adrenal and gonadal vessels enter. Thus venous control is therefore easier and safer on the left. The renal vein on the right is shorter and can tear more easily.

(D) SUPRAPUBIC CATHETER

If you want to insert a suprapubic catheter anytime in a female where it is difficult to fill the bladder, insert a uterine sound or artery forceps into the urethra. Then go just above the pubic bone and make a stab incision over the sound/ artery and pull in a Foley catheter.

(E) NELATON CATHETERS



These are an alternative to using a Foley catheter. The main advantage is that they are less likely to get blocked as the urine channel occupies the full diameter with no balloon channel.

Also, plastic catheters are less likely to kink. They are particularly useful if:

- The urethra is being reconstructed and it is only possible to insert a smaller size catheter e.g. 12 or 14F.
- In cases where the bladder is very small and it is difficult to inflate the balloon of the Foley.
- Some surgeons use them routinely because of the low risk of blockage.

The catheter has to be secured with a suture inserted just above the urethral meatus. To further secure the catheter, after tying the suture around the catheter, the suture ends are left long and wrapped in tape around the catheter. There is a risk of the catheter falling out as the stitch pulls through which is more likely after 7-14 days so this is a potential problem if you want them in for longer.